



PATIENT PRESENTING CLINICAL SIGNS

Harley Sullivan History: vomiting, Hx of eating things

ULTRASONOGRAPHIC EXAMINATION OF THE ABDOMEN

SPECIES

Canine Urinary System

The urinary bladder mucosa, trigone, and visible urethra are normal in thickness and there is no evidence of mucosal irregularities. The bladder lumen is extremely empty and bladder thickness is considered normal for volume of urine.

BREED

Mix The left kidney is normal in size, shape and architecture with smooth peripheral margins and measures large 6.65 cm. There is normal corticomedullary distinction and normal echogenicity. There is no evidence of pyelectasia, nephroliths, infarcts or hydroureter.

SEX

Female Spayed The right kidney is normal in size, shape and architecture with smooth peripheral margins and measures 6.20 cm. There is normal corticomedullary distinction and normal echogenicity. There is no evidence of pyelectasia, nephroliths, infarcts or hydroureter.

AGE

1 year **Adrenal Glands**
The left adrenal gland is slender (cranial pole 0.48 cm / caudal pole 0.43 cm). The left adrenal gland has normal in shape and is normal in appearance and echogenicity.

WEIGHT

54 lbs The right adrenal gland is slender (cranial pole 0.69 cm / caudal pole 0.39 cm). The right adrenal gland has normal shape and it is normal in appearance and echogenicity.

INTERPRETED BY

Jessica Midence, DVM,
DACVIM (SAIM)

Spleen

The splenic echotexture is homogeneous with parenchyma hyperechoic to liver and renal cortical parenchyma. The capsule is smooth with no irregularities. The splenic vasculature is normal without signs of congestion or thrombosis.

Liver

The liver is subjectively normal in size with normal contours, structure, with smooth peripheral margins. The echogenicity appears hypoechoic with increased portal markings. No overt evidence of infiltrative or regenerative pathology is evident. The visible portions of the vasculature and biliary tract appear normal. No pathological hepatic lymphadenopathy observed.

IMAGING PERFORMED BY

Jenn

HOSPITAL NAME

Rockaway AH

The gallbladder lumen is moderately distended with anechoic bile. The wall is a normal thickness and smooth. Luminal contents are anechoic. The cystic and common bile ducts are normal/not visible.

REFERRING VET

Dr. Maniar

Gastrointestinal Tract

The gastric lumen is empty. The stomach wall is of normal wall thickness with some variability due to rugal folds. There is normal gastric wall layering. There are no masses or focal lesions observed and the pyloric outflow tract appears normal.

INVOICE

The visualized areas of duodenum, jejunum and ileum appear normal in thickness. The duodenum is normal with distinct wall layering. The remainder of the small intestines are normal with normal wall layering. The lumen of the small intestine was empty with no signs of ileus, obstruction or foreign material. No focal lesions observed.

12697

The sections of colon are visualized with formed fecal material and gas shadowing distally.

DATE

4.7.23

Pancreas

The pancreas was not thoroughly evaluated given the loops provided. The area of the pancreas that could be evaluated is normal and isoechoic to surrounding mesentery. There is no evidence of nodules or cystic lesions. There is no evidence of regional mesenteric inflammation or fluid. The visible pancreatic duct was normal.

Peritoneum

Evaluation of the peritoneal cavity did not reveal any evidence of effusion, or subjective lymphadenomegaly. The omentum is of normal uniform echogenicity.

ULTRASONOGRAPHIC FINDINGS

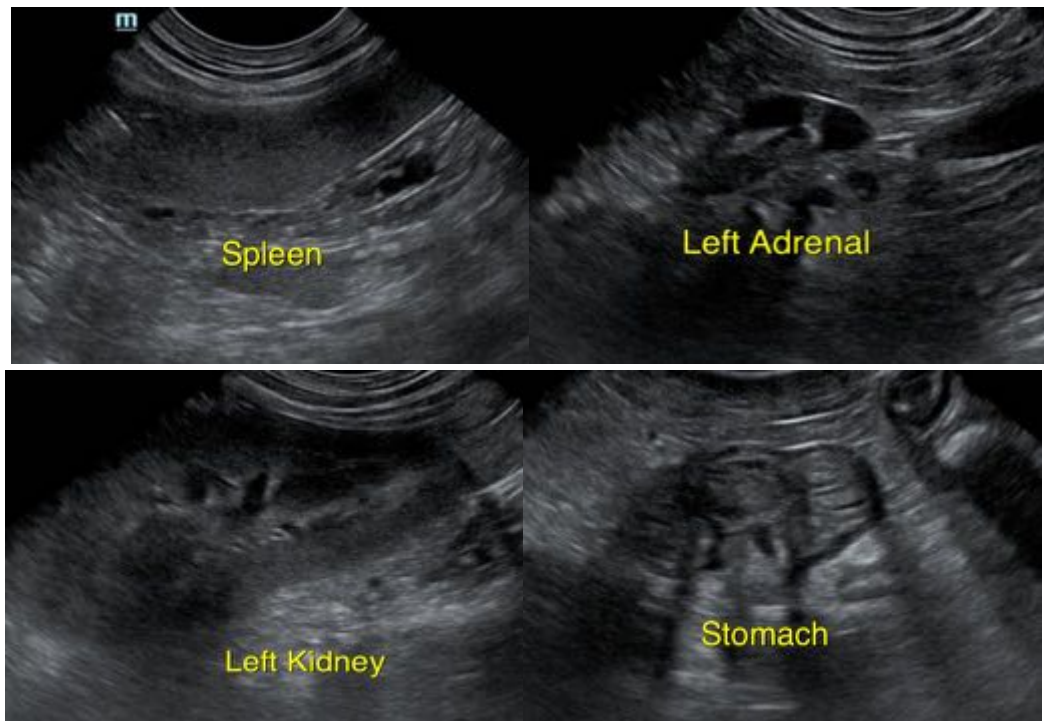
Findings

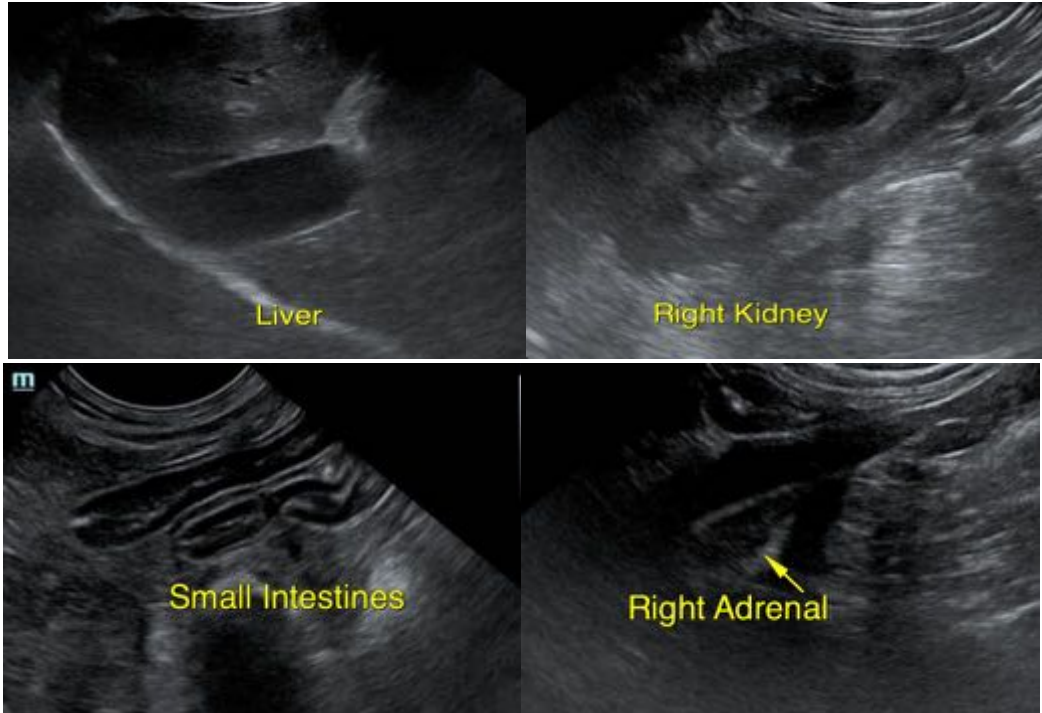
- Hypoechoic liver
- Slender adrenal glands

INTERPRETATION OF THE FINDINGS & FURTHER RECOMMENDATIONS

There is no obvious cause for vomiting on this sonographic study (no obvious pancreatitis, foreign bodies or gastroenteritis). Though the liver is hypoechoic, it could be reactive to gastroenteritis. Correlate with the lab-work findings. Treat for acute gastroenteritis with antiemetics and gastric protectants.

Also the adrenal glands measure within normal limits but are slender given the size of the patient. If lab-work suggests or vomiting continues, consider a baseline blood cortisol to evaluate for hyperadrenocorticism.





The information and recommendations provided are based on the images presented by the referring veterinarian/sonographer. No evaluation can be communicated regarding pathology that was not visible in the image/video clips provided.

Thank you for this referral. If the clinical or image interpretation does not parallel your findings or if I can be of any further assistance, please contact me.

Jessica Midence, DVM, DACVIM (SAIM)
info@SonoPath.com